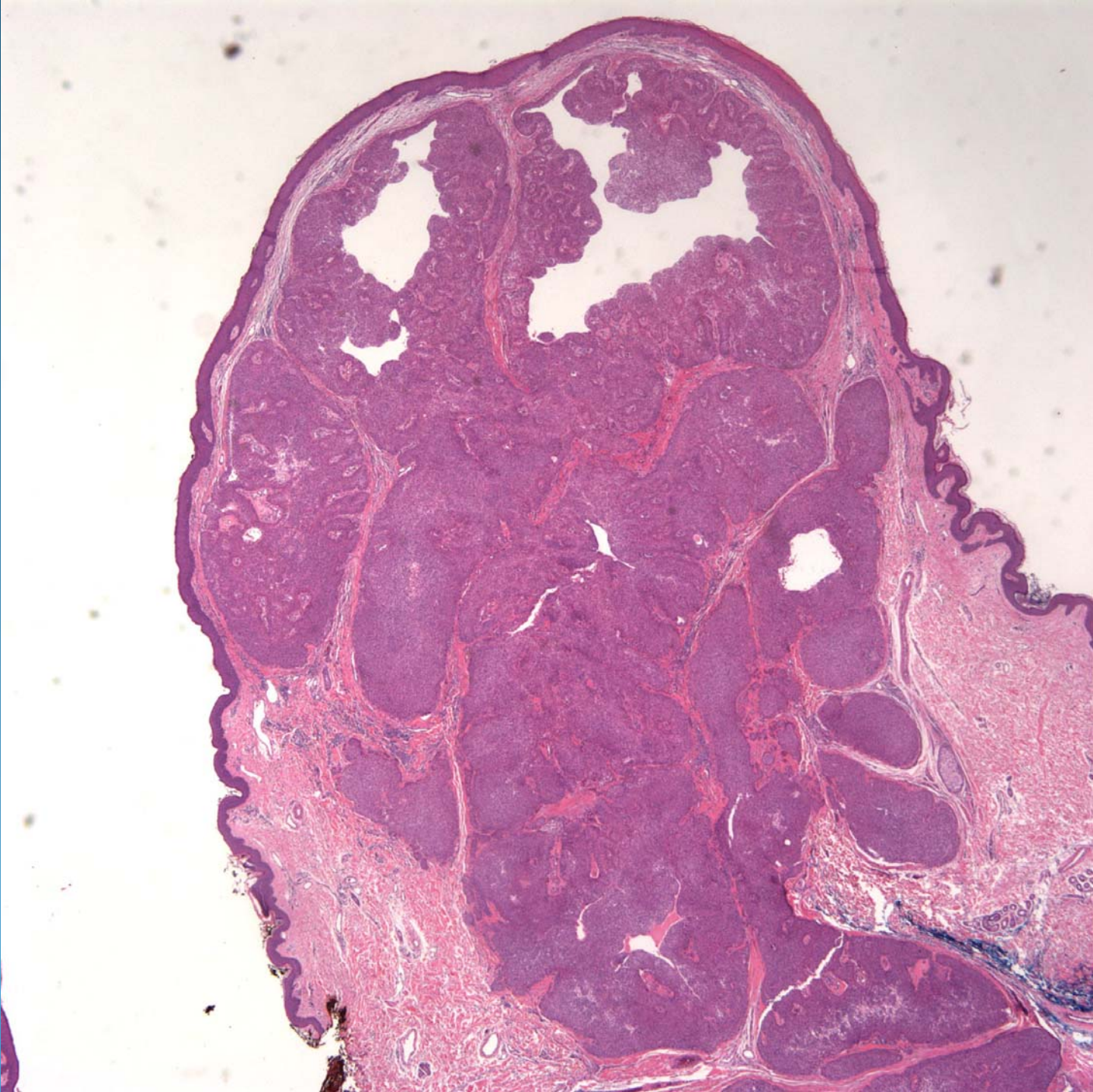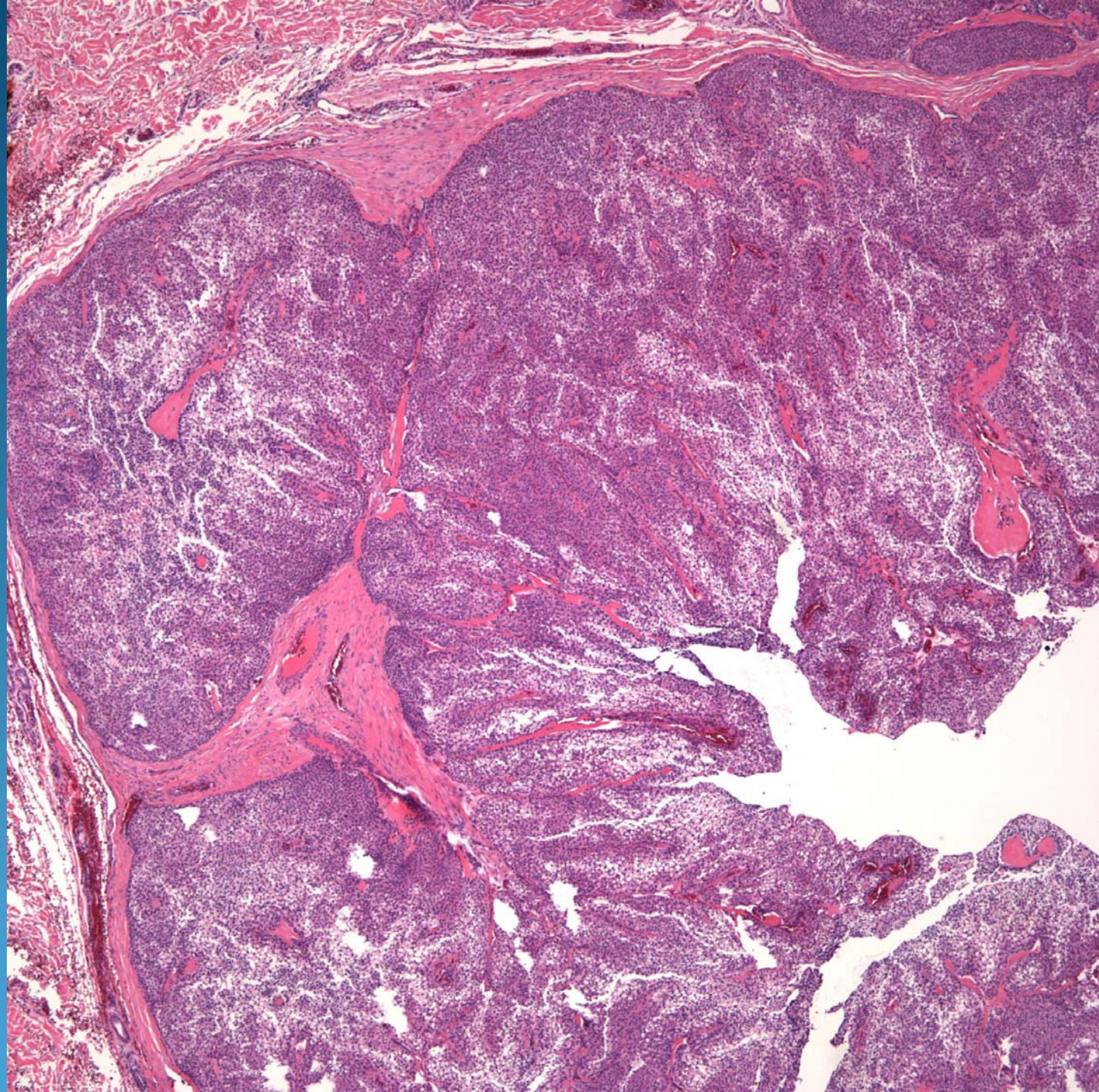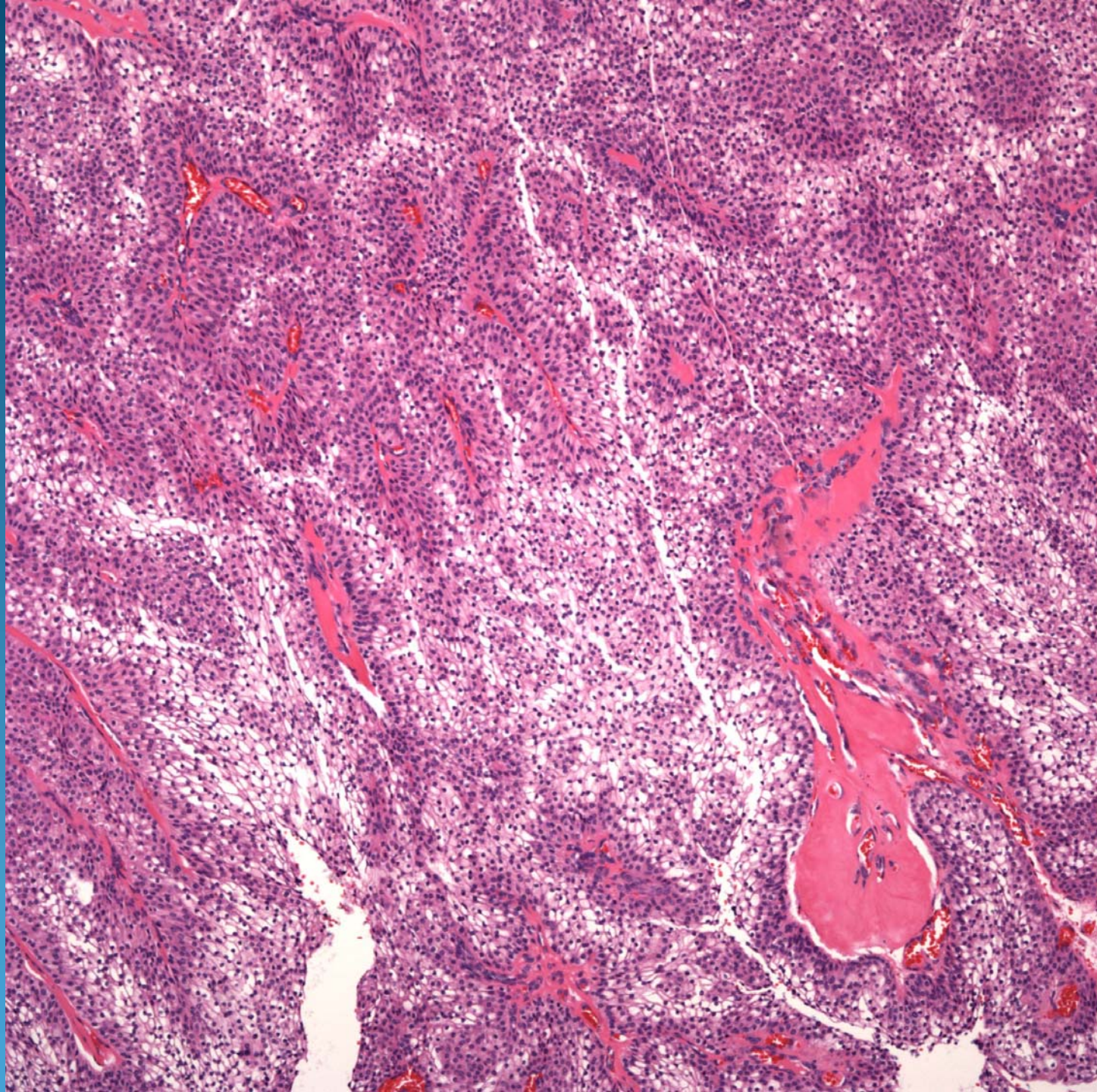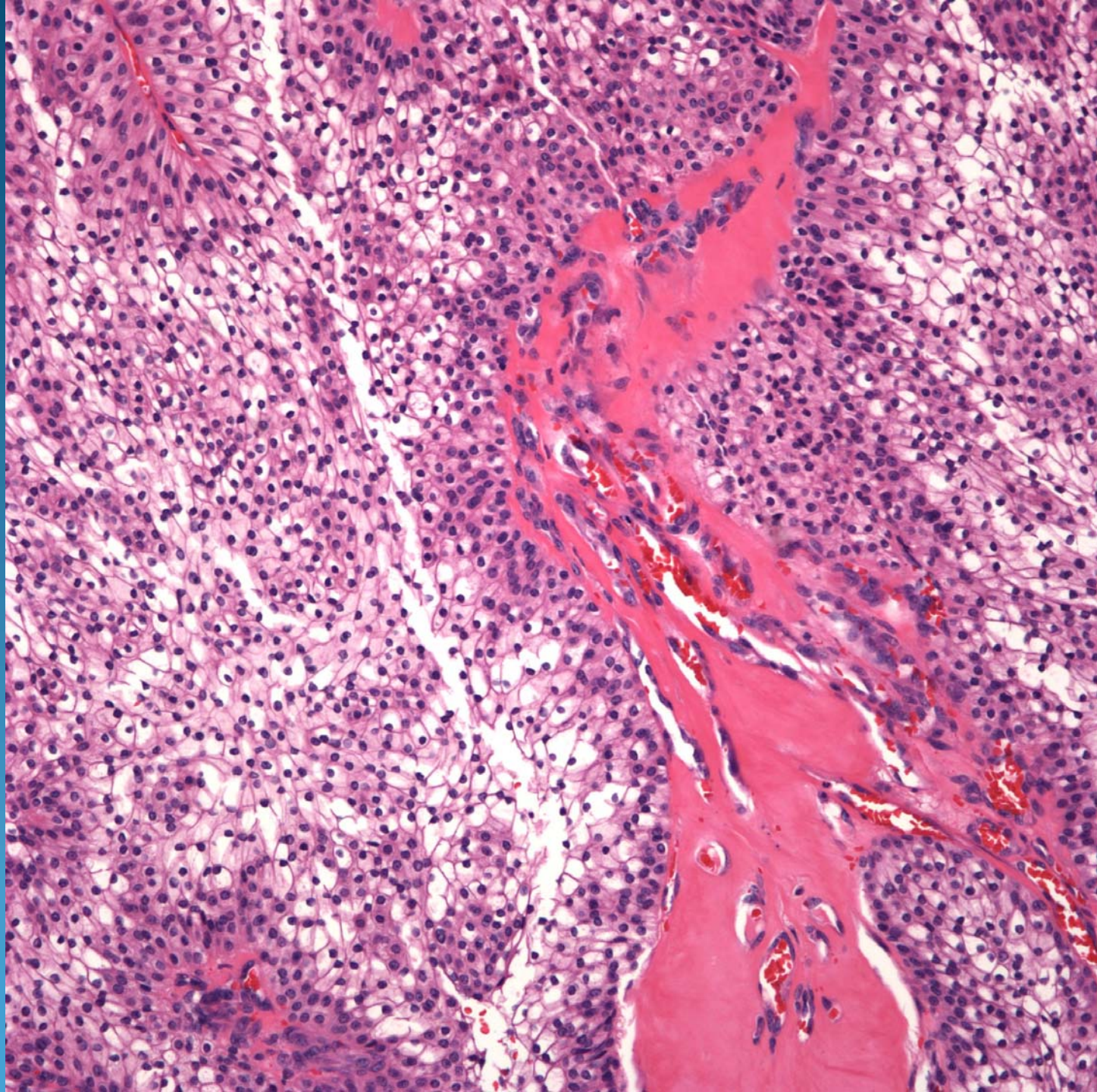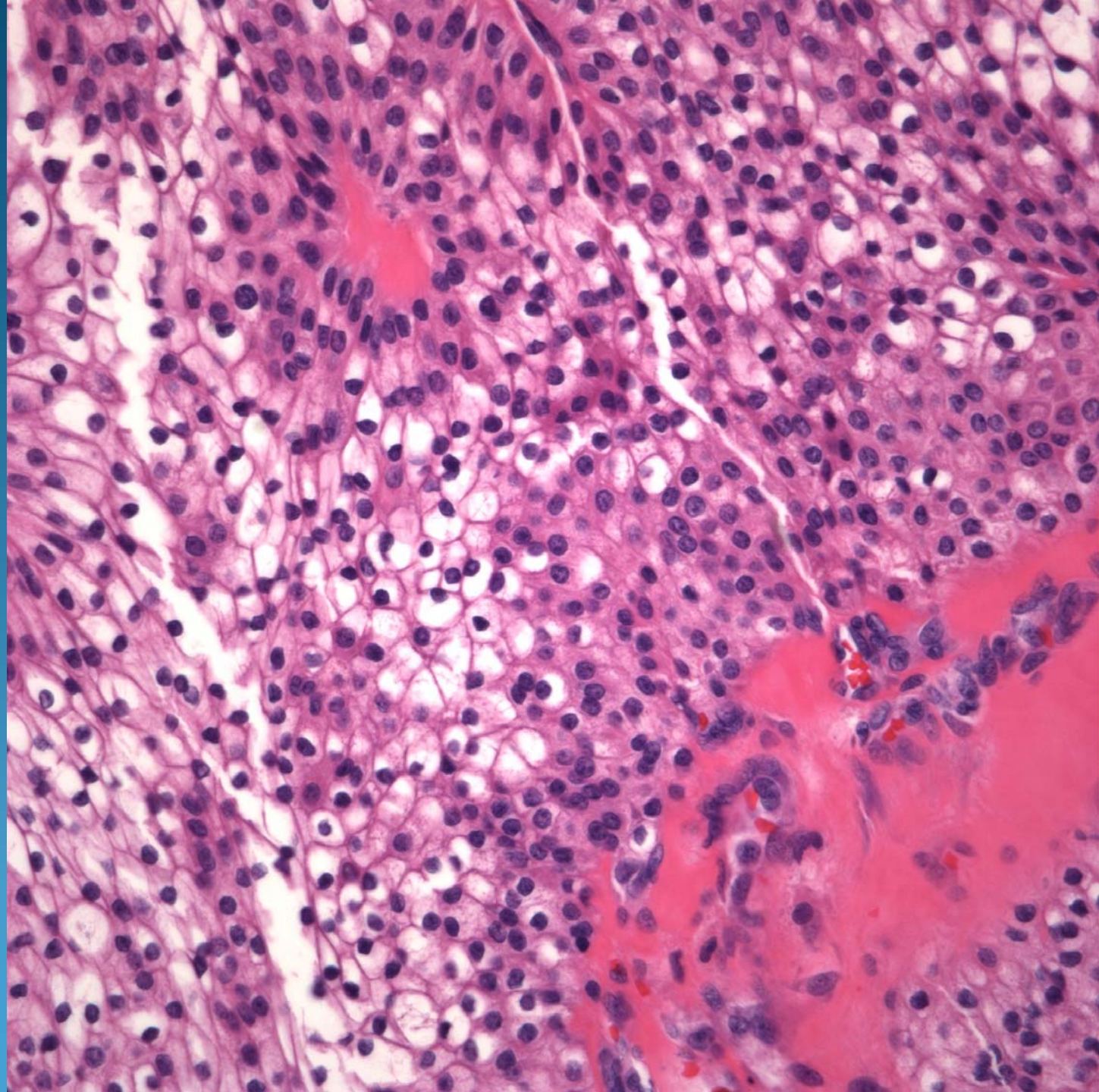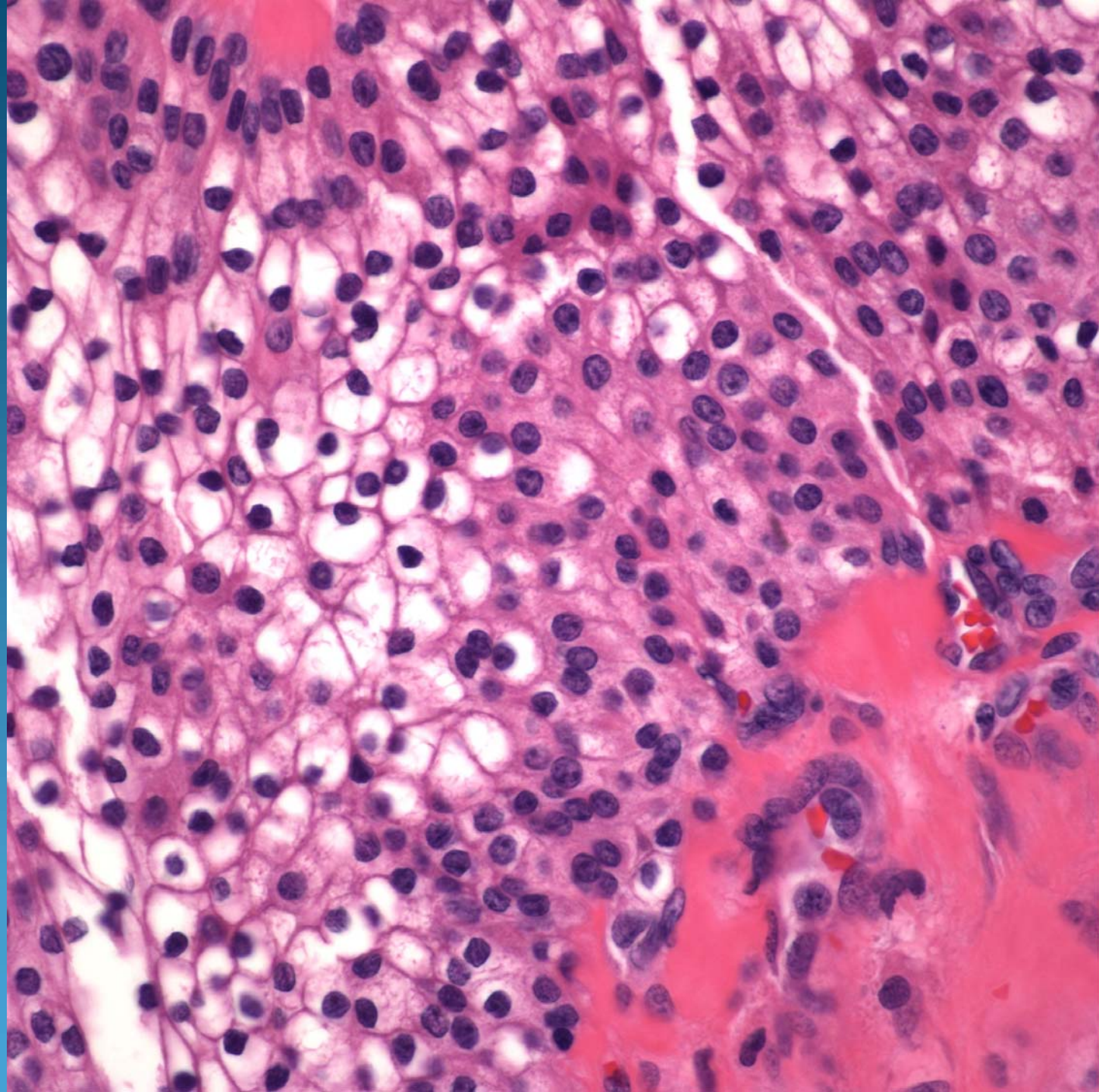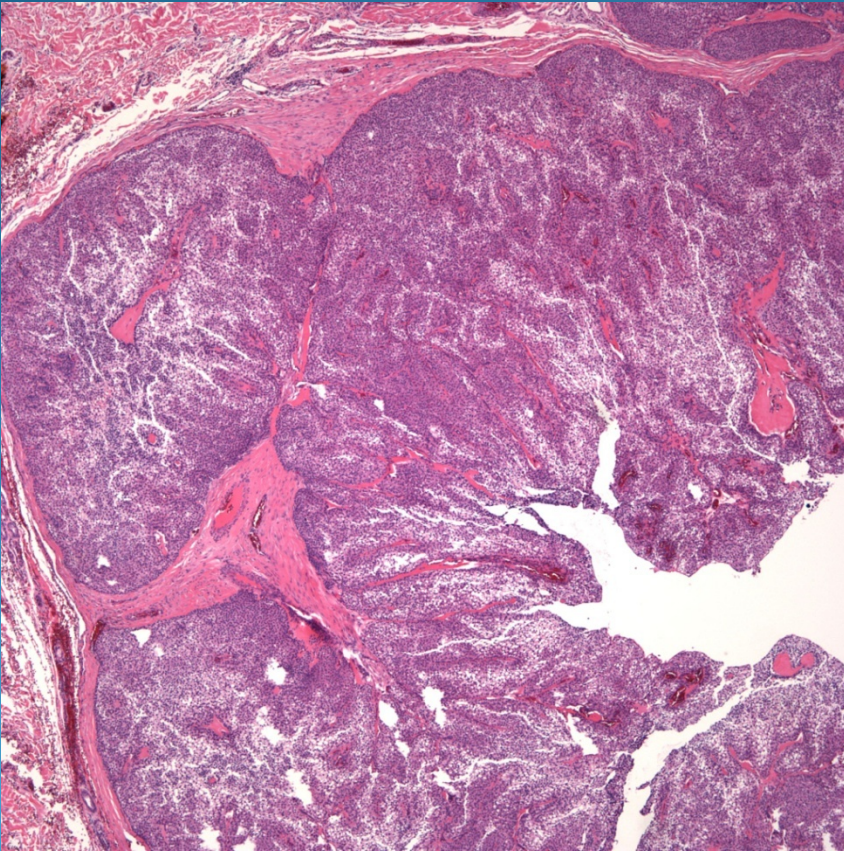


Nodular and Cystic Hidradenoma with Clear Cell Features

Pearls



- Circumscribed epithelial tumor which may have epidermal attachment
- Composed of squamous cells with clear cytoplasmic features
- Focal ducts coalescing to form larger cysts
- Hyalinization around vessels
- Rule out metastatic renal cell carcinoma